

Novel Laser Therapy in Treatment of Onychomycosis

Jasmina Kozarev,¹ Zdenko Vižintin²

¹Dr.Kozarev Dermatology Laser Clinic., Sremska Mitrovica, Serbia

²Fotona d.d., Ljubljana, Slovenia

ABSTRACT

A clinical study was performed in which 72 patients with 194 nails affected by onychomycosis were treated with long pulse Nd:YAG laser light (Dualis SP, Fotona, Slovenia) at a single clinical site (Dr. Kozarev's Dermatology and Laser Clinic) over a period of 18 months. Mycotic cultures were taken from all affected nails and various fungal infections were positively diagnosed in all 72 patients. Laser treatment consisted of four sessions with one week interval, during which all infected nails were irradiated three times with laser light so that the nail plate was fully covered each time. Fluences of 35-40 J/cm² were applied at pulse duration of 35 msec to develop a nail-plate temperature of 45°C±5. Follow up was performed at 3, 6, 9 and 12 months, with mycological check ups at 3 and 6 months. At the 3 month follow up point, 95,8% of patients were cleared of all fungal infections. The full procedure was performed again on the three patients in which infection persisted after 3 month follow up (4,2%). On 6 and 12 month follow up all patients (100%) were clear of all fungal infection. There were no noticeable side effects of treatment and all patients were satisfied with treatment. This clinical study demonstrates that fungal nail infections can be effectively and safely treated with VSP Nd:YAG 1064 nm laser.

Key words: onychomycosis, nails fungal infection, Nd:YAG lasers,

Article: J. LAHA, Vol. 2010, No.1;pp. 1-8.

Received: April 03, 2010; Accepted: April 30, 2010.

©Laser and Health Academy. All rights reserved.
Printed in Europe. www.laserandhealth.com

I. INTRODUCTION

Onychomycosis, a persistent fungal infection of the nail bed, matrix or plate, is the most common nail disorder in adults, accounting for one third of all fungal skin infections and up to 50 percent of all nail diseases [1-3]. Toenails are affected more often than fingernails. The causative agents of onychomycosis

include dermatophytes (fungi that invade only dead tissues of the skin, nails, or hair), nondermatophyte moulds, and rarely, yeasts of the *Candida* species [4]. The dermatophytes *Trichophyton rubrum* and *Trichophyton mentagrophytes* are the most common causative pathogens of onychomycosis, with *T. rubrum* responsible for approximately 90 percent of all cases [1,2]. The overall prevalence of onychomycosis ranges from 2 to 14 percent. The risk of infection increases with age: 15-20% of persons between the ages of 40 and 60 have the condition, 32% of those who are between 60 and 70, and 48% of those older than 70 [1]. Recent evidence suggests that the incidence of onychomycosis is increasing [1,2]. Several conditions can mimic onychomycosis, including psoriasis, atopic dermatitis, nail trauma, contact irritants, and lichen planus.

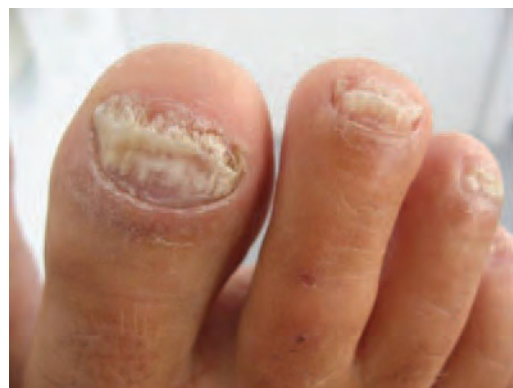

Fig. 1: An example of severe distal subungual onychomycosis

Therapeutic options for the treatment of onychomycosis include palliative care, mechanical or chemical debridement, topical and systemic antifungal agents, and various combinations of these modalities. The choice of therapy is influenced by the presentation and severity of the disease, other medications that the patient is taking, which previous therapies for onychomycosis have already been attempted (and their effects), physician and patient preference, and cost. [5]

Treatments of advanced onychomycoses are time-consuming, cost-intensive, and subject to relatively high failure rates. Even drug courses of potent systemic antimycotics, delivered over a period of several months, have cure rates of only 40 to 80% [23-25]. Among the orally delivered systemic drugs Terbinafine, Intraconazole and Fluconazole are most frequently used. Systemic drug therapy is associated with several unpleasant side effects. Headache, rash and gastrointestinal symptoms were reported in about 7 percent of patients treated with Intraconazole [23] and about 5 percent of patients treated with Fluconazole suffered nausea, headaches, pruritus and liver enzyme abnormalities [26]. The duration of systemic drug therapy is usually three months; the duration can be cut in half by using "pulse" therapy, in which increased doses are administered.

Topical antifungal preparations are also widely used. Although safe and relatively inexpensive, topical therapy is seldom effective [27].

The efficacy of the treatment can be improved and its duration reduced by supplementing the medicamentous therapy with some complementary (e.g. light) treatment. Photodynamic therapy has been recently proposed to treat *T. rubrum* infection, and promising results have been obtained [6].

The direct effect of laser light on fungal isolates and affected nails has not yet been rigorously examined for its possible inhibitory potential.

Although there are already two laser system manufacturers promoting their systems for the treatment of onychomycosis, thus far neither has delivered a clinical study with a significant number of cases in which an efficacious outcome was achieved.

II. MATERIALS AND METHODS

194 nails of 72 patients with clinically and mycologically proven onychomycosis were exposed to transcutaneous laser irradiation with the aim of deactivation and eradication of fungal infection.

Inclusion criteria

To take part in the study each patient had to have one or more toenail and/or fingernail fungal infections of the follow types: total dystrophic form, distal subungual onychomycosis, proximal subungual onychomycosis and/or endonyx onychomycosis and be between 18-45 years of age.

All patients signed written informed consent statements before beginning laser treatment.

Exclusion criteria

Patients who used systemic antifungal, oral antifungal therapy, or isotretinoin within 6 months of the first scheduled laser procedure were excluded. Some examples of drugs which were cause for exclusion are griseofulvin or other cefalosporins, minocyclin, or cytostatics (busulfa, 5-fluorocil). Patients who used vasodilators were also excluded, because faster blood flow could increase heat transfer in the nail plate, thereby adversely effecting therapy.

Permanent or semi-permanent discoloration of the nail plate was another cause for exclusion. Such discoloration can be caused by the use of therapeutics or cosmetics which effect nail pigmentation, for example the local antifungal therapy solutio Castellany, the use of nail dyes and polishes (especially those which contain magnesium or iron). Discoloration can also be caused by professional exposure to dyes or asphalt.

The following conditions can cause various physiological changes to the nail plate in addition to discoloration and so were also cause for exclusion: subungual hematoma, nevoid subungual formation, bacterial nail infections, and concomitant nail disorders such as psoriasis of nail plate, lichen planus and atopic dermatitis.

In addition, pregnant women were excluded.

Treatment procedure

The primary aim of this treatment regime was to restore the nail to full health at 12 months. The secondary aim of treatment was to render the nail free of fungi at 3 months.

In the first step samples were collected and the nail area was thoroughly cleansed with alcohol to remove contaminants. For distal subungual onychomycosis, the infected nail was clipped proximally and the nail bed and underside of the nail plate were scraped with a 1-2 mm serrated curette. For proximal subungual onychomycosis, the normal surface of the nail plate was pared down with a no.15 surgical blade at the lunula and the white debris was collected with a sharp curette from the deeper portion of the plate and the proximal nail bed. The sampled material was divided into two portions: one for direct microscopy and the remainder for culture.

Prior to laser treatment positive fungal cultures were obtained from all patients after direct microscopy was used as a screening test. Scrapings were mounted for direct examination in 25% KOH mixed with 5% glycerol, heated (e.g., for 1 h at 51 to 54°C) to emulsify lipids, and examined under 3400x magnification for

fungal structures. Culture examination was executed by an independent microbiological laboratory (Mikrobioloska laboratorija Paster, Belgrade, Serbia).

Of the 110 patients who were initially recruited, 72 (65%) tested positive for, and were microbiologically confirmed as carrying, fungal cultures. All 72 patients were included in the study and completed all treatment sessions and follow ups.

Thicker nails were pretreated to achieve better laser light penetration. The patient's thick dystrophic nails were treated with a preparation containing: 40% urea, 20% anhydrous lanolin, 5% white wax, and 35% white petrolatum for three successive nights, by applying the preparation to the nail under occlusion. This pretreatment was only needed for 3 patients of 72 (4%).

Treatment was performed using long pulse VSP 1064 nm Nd:YAG laser (Dualis SP; Fotona, Slovenia), with fluences in the range of 35 to 40 J/cm², a spot size of 4 mm diameter, and pulse duration of 35 ms. The variations in fluence were selected based on the thickness of the nail to be treated, with thicker nails requiring higher fluence. The pulse rate was 1 Hz. The laser beam was applied to the entire nail plate by incrementally moving the beam in a spiral pattern as shown on Fig. 2. After the entire nail plate was irradiated a 2 minute pause was taken and then the treatment and pause were repeated twice more for a total of three passes. The total therapy consisted of four sessions with a one week interval between each session.




Fig. 2: Presentation of delivery of laser beam in spiral pattern on the nail plate surface (a) Thermal images of toenail surface before (b), and after (c) irradiation with VSP Nd:YAG laser beam. Temperature increase of the nail plate is clearly visible.

For the first few patients the temperature increase of the nail plate was measured during treatment using FLIR Thermal Imager and ThermoCAM Researcher

Pro 2.8 software with which the level of temperature increase was determined (see Fig.2 b) c) and Fig.4).

No local anesthesia was applied preoperatively. Cold air cooling was applied to the area during laser treatment, (Cryo6, Zimmer, Germany used). No postoperative analgesic treatment was required. No prophylactic antibiotics or antiviral were given to any patient.

Parallel to in-vivo therapeutic irradiation of nails infected with fungi an in-vitro experiment of laser irradiation effect on fungus culture was performed. An isolate of fungal colonies obtained from a toenail scraping were passed on Sabouraud Peptone-Glucose Agar. Ten days after isolation standardized photographs were obtained; the colonies were exposed to laser irradiation with 1064 nm wavelength, fluence of 40 J/cm² and pulse duration of 35 msec. Three days after laser exposure a final examination was made and standardized photographs were obtained.

Treatment Evaluation

Follow-ups were done at 3, 6, 9 and 12 months. The patients were evaluated for clearance of fungal infection clinically by the physician executing the procedure and mycologically by analysis of the culture taken at 3 and 6 month follow-up visits made by independent microbiological laboratories (Mikrobioloska laboratorija Paster, Belgrade, and Belladonna, Zemun, both Serbia). Photographs were taken using the same camera settings, lighting, and nail position at baseline and at the 6, 9 and 12-month follow-up visits.

Also, all the patients were filling-in questionnaires after each therapeutical session, evaluating the level of procedural pain (on a 5-point scale where 0 = no pain, 1 = mild pain, 2 = moderate pain, 3 = severe pain and 4 = intolerable pain) as well as possible adverse effects, if any of such would occur.

III. RESULTS

a) Types of onychomycosis treated

Treated patients had all four major clinical types of onychomycosis: total dystrophic form, distal subungual onychomycosis, proximal subungual onychomycosis and endonyx onychomycosis. The distribution of onychomycosis types in patient population is given in Table 1.

Table 1: Clinical types of fungal nail infection in treated group.

Type of onychomycosis	Number of patients (%)
Total dystrophic	6 (8.3%)
Distal subungual	38 (52.8%)
Proximal subungual	22 (30.5%)
Endonyx	6 (8.3%)

b) Types of diagnosed fungal infections

As expected, the most frequent fungus found among treated patients was *Trichophyton rubrum* (in 37 patients or 51,4%), followed by *Trichophyton mentagrophytes* (22 patient or 30,5%). Table 2 presents all fungi found in patient population.

Table 2: Types of fungal nail isolates.

Type of fungal isolates	Number of patients
<i>Candida sp.</i>	10
<i>T. rubrum</i>	37
<i>T. mentagrophytes</i>	22
<i>Aspergillus niger</i>	3

c) Eradication of nail fungal infections

On 3 months follow up 95,83% patients were cleared of all fungal infections. On 3 patients (4,17%) with still present infection the complete procedure was repeated. On 6 and 12 months follow ups all patients (100%) were fully cleared of all fungal infections.

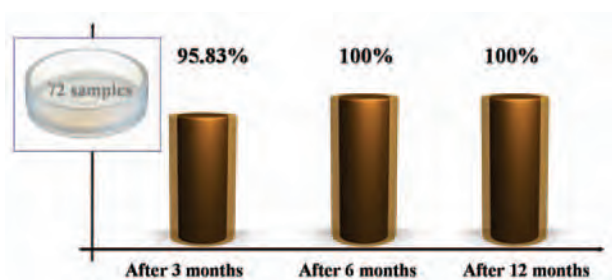


Fig. 3: Efficacy of laser treatment of onychomycosis, as observed from mycological cultures taken on 3 and 6 months and clinically evaluated on 12 months.

d) Temperatures measured on the nail plate

Measurements of the nail plate temperature showed similar behaviour on all tested specimens.

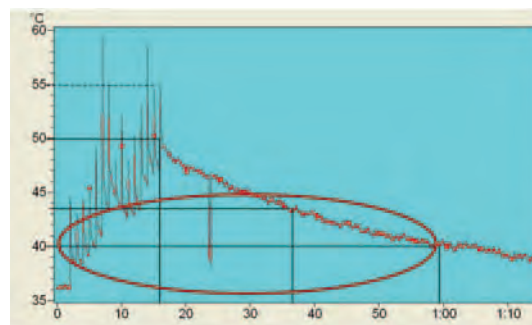


Fig. 4: Measured temperature at the nail plate during the laser treatment.

Working with laser energy delivery rate of 1 Hz and using spot size of 4 mm, the nail plate was fully covered with laser energy in approximately 15 seconds. During that time the temperature in average increased to about 50°C. After the delivery of energy was stopped, the nail plate cooled, reaching 40°C in about 1 minute after the beginning of irradiation.

e) Treatment pain and adverse effect evaluation

Patients evaluated the treatment pain level after each of the four sessions. Their evaluations were averaged and the results are presented in Table 3 below. Most of the patients reported mild pain, while none reported severe or intolerable pain.

Table 3: Patients averaged evaluation of treatment pain.

Pain level	No. of patients (%)
(0) No pain	26,39
(1) Mild pain	45,83
(2) Moderate pain	27,78
(3) Severe pain	0,00
(4) Intolerable pain	0,00

Many of patients developed a kind of pain resistance during the therapy. Usually they felt the highest level of pain during the first session. In following sessions patients' pain scores were usually lower, as they become "adapted", or they already knew what pain level they could expect.

Patients were also asked to report all adverse effects. There were no reports of unwanted side effects resulting from treatment.

f) In-vitro fungus eradication

All in-vitro irradiated samples of fungal cultures were showing evident growth inhibition and colonies decay after single irradiation session. Example of an in-vitro fungal colony development, prior to laser irradiation is shown on Fig.5 a) and its diminishing after the irradiation is shown on Fig.5 b).

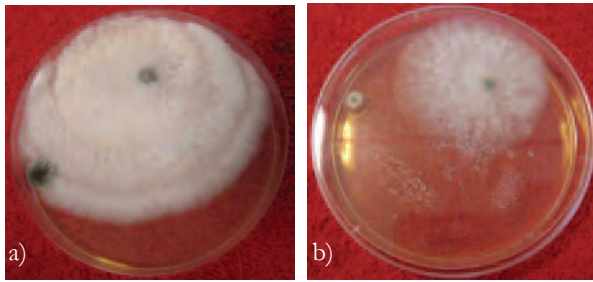


Fig. 5: Petri dish with *T. mentagrophytes* before and 3 days after long pulse VSP Nd:YAG laser irradiation.

IV. DISCUSSION

Dermatophyte cells infect skin by a process of adherence to the cells of the epidermis followed by germination, growth, and penetration by fungal hyphae, both within and between cells. The first phase of fungal attack on the stratum corneum, the outer layer of cornified cells, dead cells filled with the fibrous protein, keratin, depends on this process of intercellular adherence. Initial studies of this phenomenon utilized microconidia obtained from pure dermatophyte cultures. [14]

The principle means of defense against dermatophytes identified at present involve both non-immunological processes such as the interaction between fungi and unsaturated transferrin, activation of epidermal peptides, the inhibitory effect of fatty acids in sebum, and immunological processes including fungal killing by polymorphonuclear leucocytes attracted into the area of infection as well as the activation of T lymphocytes [14].

Increasingly onychomycosis is being viewed as more than a mere cosmetic problem. Persons with unsightly, infected nails may suffer embarrassment. Fungi from the nails may precipitate secondary bacterial infections, cellulitis, idiopathic reactions and chronic urticaria. Infected toenails may act as a reservoir for fungi, facilitating their transmission to other areas of the body and even to other people.

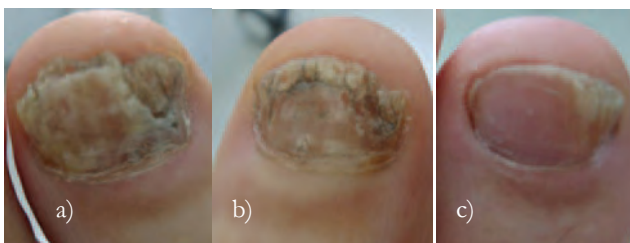

Fig. 6: *Trichophyton rubrum* treated with VSP Nd:YAG laser: before a), 6 months after b) and 12 months after c)

Clinical diagnosis of onychomycosis is based on the patients' history; a physical examination, microscopy

and culture of nail specimens. Predisposing factors like diabetes, old age, hyperhidrosis, onychoglyphores, nail trauma, poor peripheral circulation are likely to be present. Several nail disorders that may mimic fungal nail infections must be correctly recognized and differentiated from onychomycosis to initiate the most appropriate therapy. They include psoriasis, lichen planus, bacterial infections, contact dermatitis, traumatic onychodystrophies, paronychia congenital, nail bed tumors, yellow-nail syndrome, idiopathic onycholysis etc.

There are a lot of factors which are contributing to fungal nail infection such as: diabetes, professional exposure to sugar (cooks, confectioneries, candy makers, sportsmen), exposure to traumas (minor or mayor trauma like subungual hematomas), activities contributing to excessive sweating of feet and skin maceration, visits to pedicure treatments.

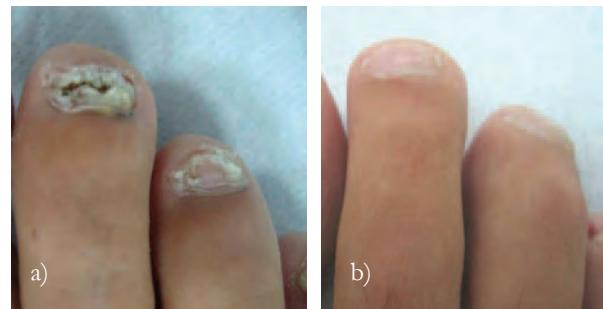

Fig. 7: *Trichophyton mentagrophytes* treated with VSP Nd:YAG laser : before a) and 12 months after b)

Each of the four clinical types of onychomycosis, as defined by the route of fungal invasion, has a characteristic appearance, but other diseases, particularly psoriasis, may have a similar appearance. Proper management, therefore, includes confirmation of fungal infection by potassium hydroxide slide preparation and culture.

Traditionally, pharmacologic treatment has been less than optimal. In many cases, griseofulvin, the first oral agent approved for onychomycosis, must be given for a year or more to be effective. Low cure rates are related to poor bioavailability and the fungistatic rather than fungicidal effect of the drug. Newer agents, such as oral itraconazole and oral terbinafine, promise to substantially increase cure rates while shortening treatment duration. Oral terbinafine is potently fungicidal against dermatophytes and has proven efficacious with regimens as brief as 12 weeks when infection is not spread over the entire nail [23-25].

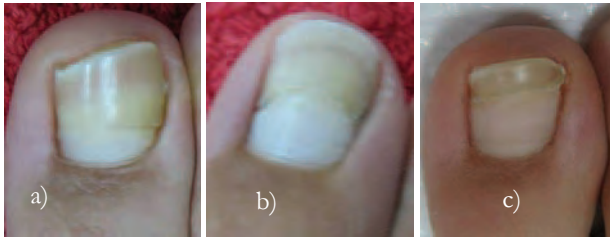

Fig. 8: Candida species treated with VSP Nd:YAG laser: before a), 6 months after b) and 9 months after c)

The successful clinical use of lasers largely depends upon the wavelength, output power, pulse duration, exposure time, spot size, type, and color of the targeted tissue [8,10,13].

One of main advantages of laser surgery is its bactericidal effect. Laser light causes local hyperthermia, destruction of pathogenic microorganisms, and stimulation of the reparative process [28]. Statistically significant growth inhibition of *T.rubrum* was detected in colonies treated with the 1,064-nm Q-switched Nd:YAG laser at 4 and 8 J/cm² [29]. This laser produced a significant inhibitory effect upon the fungal isolate *T.rubrum* in an in-vitro study. Meral, Tasar at al. reported a strong bactericidal effect on *Candida albicans* suspensions after Nd:YAG laser irradiation [30].

The laser used in this study –VSP Nd:YAG 1064 nm, penetrates through the nail plate and produces heat deep within the dermis and nail tissue.

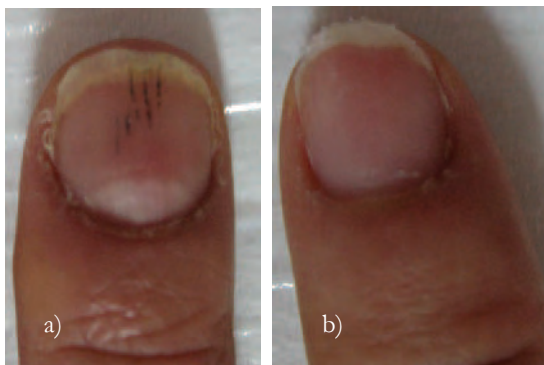


Fig. 9: Aspergillus niger treated with VSP Nd:YAG laser: before a) and 6 months after b)

Melanin is an essential constituent of the fungal cell wall that has been described in many pathogenic species. The type of melanin varies although it is commonly Dopa or pentaketide melanin. Melanized fungal cells show enhanced capacity to resist T-cell mechanisms and neutrophil attack largely through neutralizing the effect of oxidative products such as superoxide or reactive oxygen. Dermatophyte infections are normally eliminated through a Th1 path

involving effector mechanisms that range from accelerated epidermal turnover to production of adhesion molecule-directed neutrophil trafficking in the epidermis at the site of infection and subsequent phagocyte-mediated fungal cell destruction.

The 1064 nm radiation emitted by the Nd:YAG laser is primarily absorbed by dark pigments. When an Nd:YAG laser is used at high power settings and for a long time, the rise in temperature has deleterious effects on periodontal tissues [8]. It is generally agreed that temperatures above 56-60°C cause denaturation of hard tissue proteins [7,8] Eriksson & Albrektsson reported that 47°C temperature for 1 minute (only 10°C above human body temperature) produced persistent bone damage [11,12]. Levy et al. demonstrated the level of energy is a critical factor to obtain safe treatment conditions [13].

Local hyperthermia has been a common therapy in Japan in the treatment of sporotrichosis since 1966, and good results have been obtained [21]. It was applied with infra red and far infra red devices. The disadvantages of these methods were related to the application of non sophisticated devices and the necessity of daily applications.

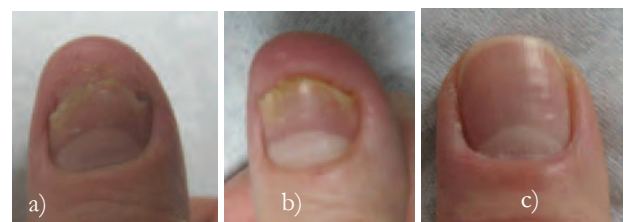

Fig. 10: Candida species treated with VSP Nd:YAG laser : before a), 3 months after b) and 9 months after c)

Desired average tissue temperature for laser irradiation of onychomycotic nails is about 43-51°C, at a treatment time of at least 2-3 minutes; these parameters provide an adequate therapeutic dose. Toleration of higher temperatures is possible with desensitization of the treated area or with increased blood flow.

The amount of laser energy that can deactivate 80-99% of the organisms present in an affected nail is the deactivating dose. That dose does not instantly kill the fungal colonies but results in their disability to replicate or survive according to apoptotic mechanism.

Apoptosis, a physiological type of cell death, plays an important role in the selective deletion of cells in divergent situation of various tissues (Levine et al, 1991; White, 1995). The events that are able to induce apoptosis are incredibly diverse but are generally

classified into one of three categories: induction by direct DNA damage e.g. strand breaks, chromosomal aberrations, induction by transduced signals e.g. FAS/APO-1 transmembrane signals, and stress (heat) mediated apoptosis. Hyperthermia, a typical environmental stress, has long been known as toxic to cells. It has been recognized the mode of cell killing to be influenced by severity of the heat treatment [18].

A number of reports have been published to demonstrate the induction of apoptosis by mild hyperthermia [19,20]. Some of the possibilities are that thermal injury may initiate a death signal, target certain heat labile proteins, or cause direct or indirect DNA damage leading to apoptosis. Apoptosis is the result of a combination of the thermal destruction (directly or indirectly) of apoptosis protecting molecules with a concurrent production of killing molecules which then execute the death sentence.

rescuing capacity of cells, induce cell death. Membrane lipid ceramide has been proposed as a signaling molecule that converts extracellular stresses into intracellular signals. In response to heat shock, ceramide levels increased in normal HL-60 cells.

HSP70 in *Trichophyton rubrum* is already detected and carefully characterised. Reactive oxygen species has recently been suggested as a second messenger generated by growth factors and cytokines, including PDGF, EGF, angiopoietin-1, TNF α , and IL-1 in nonphagocytic cells. Denatured proteins disrupt cellular redox homeostasis and increase ROS levels and ROS induces protein misfolding. When misfolded proteins are produced, proteolytic machinery is turned on to remove them [16,20]

Most severe protein denaturation leads apoptosis of fungal cell - a programmed cell death or sometimes cell suicide which plays an important role in a wide variety of normal and pathological processes.

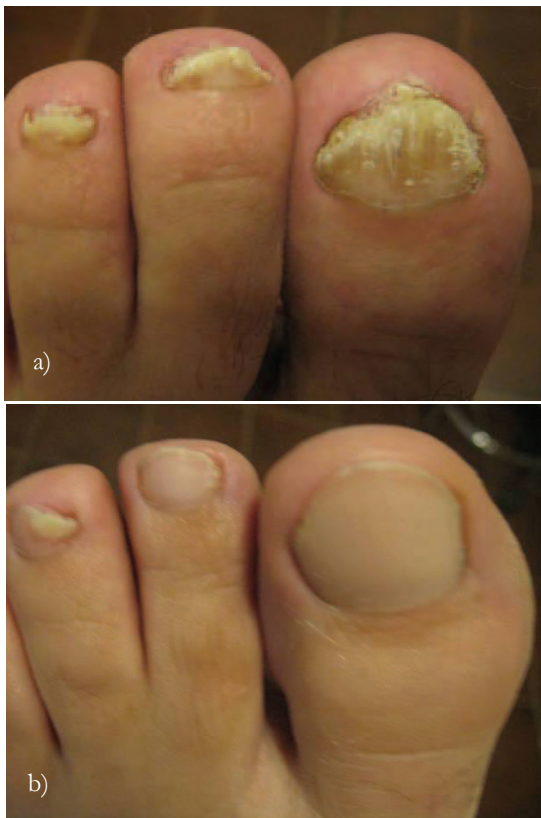

Fig. 11: *Trichophyton rubrum* treated with VSP Nd:YAG laser: before a) and 12 months after b)

External stresses including heat shock induce the generation of reactive oxygen species (ROS) and denaturation of cellular proteins. Activations of signaling pathways in response to a stress vary depending on the strength of stress resulting in the generation of various amounts of ROS and denatured proteins. Strong stress which is overflowing the

V. CONCLUSIONS

Nd:YAG 1064 nm laser irradiation with the capability of delivering destructive high energy pulses to specific targets with minimized surrounding tissue damage seems to be well suited for the task of eradicating nail fungal infection. This wavelength photo-inactivate fungal pathogens to a depth below the nail tissue surface leaving the surrounding tissue intact, using safe energy densities in-vitro and in-vivo at physiologic temperatures. Reduction of nail plate thickness before laser treatment on severely distrophic enables the optimal effect of Nd:YAG laser procedure.

The procedure is simple and quick with no noticeable side effects and complications. VSP Nd:YAG laser therapy of onychomycosis is safe and very efficient method for treating all types of onychomycosis caused by various fungal species.

This method is useful for the broadest range of patients and is specially beneficial in elderly, compromised and hepatopathic patients for which other alternative treatments could present some risks.

REFERENCES

1. Schlefman BS (1999) Onychomycosis: A compendium of facts and a clinical experience. *J Foot Ankle Surg.* 38:290–302.
2. Ghannoum MA, Hajjeh RA, Scher R, et al. (2000) A large-scale North American study of fungal isolates from nails: The frequency of onychomycosis, fungal distribution and antifungal susceptibility patterns. *J Am Acad Dermatol.* 43:641–648.
3. Zaias N, Glick B, Rebell G (1996) Diagnosing and treating onychomycosis. *J Fam Pract.* 42:513–518.
4. Evans EG (1998) Causative pathogens in onychomycosis and the possibility of treatment resistance: a review. *J Am Acad Dermatol.* 38:S32–S56.

5. Gupta AK, Ryder JE, Baran R (2003) The use of topical therapies to treat onychomycosis. *Dermatol Clin* 21:481-9.
6. Okunaka T, Kato H, Konaka C, Sakai H, Kawabe H, Aizawa K (1992) A comparison between argon-dye and excimer-dye laser for photodynamic effect in transplanted mouse tumor. *Jpn J Cancer Res.* 83(2):226-231.
7. Midda M, Renton-Harper P (1991) Lasers in dentistry. *Br Dent J.* 11;170(9):343-6.
8. Pick RM (1993) Using lasers in clinical dental practice. *J Am Dent Assoc.* 124(2):37-4. Review.
9. Hay J R (2007) Immune Responses to Dermatophytoses In: *Immune Responses to Dermatophytoses* 226-233, Springer
10. Brooks SG, Ashley S, Fisher J, et. Al (1992) Exogenous chromophores for the argon and Nd:YAG lasers: a potential application to laser-tissue interactions. *Lasers Surg Med.* 12(3):294-302.
11. Eriksson A, Albrektsson T, Grane B, et. al. (1982) Thermal injury to bone. A vital-microscopic description of heat effects. *Int J Oral Surg.* 11(2):115-21.
12. Eriksson A, Albrektsson T (1983) Temperature threshold levels for heat-induced bone tissue injury: a vital-microscopic study in the rabbit. *J Prosthet Dent.* 50(1):101-7.
13. Levy G (1992) Cleaning and shaping the root canal with a Nd:YAG laser beam : a comparative study. *J Endodon;* 18:123-7
14. Rosenberg HF, Gallin JI (1999) Inflammation. In *Fundamental Immunology*, ed Paul WE. Lippincott-Raven Publishers, Philadelphia, 1051–1066.
15. Jiang Q, Cross AS, Singh IS, Chen TT, Viscardi RM, Hasday JD (2000). Febrile core temperature is essential for optimal host defense in bacterial peritonitis. *Infect Immun* 68: 1265–1270.
16. Dubois MF, Hovanessian AG, Bensuade OI (1991) Heat shock-induced denaturation of proteins. Characterization of the insolubilization of the interferon-induced p68 kinase. *J Biol Chem* 266: 9707- 9711
17. Elia G, Santoro MG (1994) Regulation of heat shock protein synthesis by quercetin in human erythroleukemia cells. *Biochem J* 300:201-209
18. Armour EP, McEachern D, Wang Z, Corry PM, Martinez A (1993) Sensitivity of human cells to mild hyperthermia. *Cancer Res* 53: 2740-2744
19. Cuende E, Ales-Martinez JE, Ding L, Gonzalez-Garcia M, Martinez-A C, Nunez G (1993) Programmed cell death by bcl-2-dependent and independent mechanisms in B lymphoma cells. *EMBO J* 12:1555-1560
20. Deng G, Podack ER (1993) Suppression of apoptosis in a cytotoxic T-cell line by interleukin 2-mediated gene transcription and deregulated expression of the protooncogene bcl-2. *Proc Natl Acad Sci USA* 90: 2189-2193
21. Hiruma W, Kavada A et al. (1992)Hyperthermic treatment of sporotrichosis: Experimental use of infra red and far infra red reys. *Mycoses* 35, 293-299
22. Gupta AK, Ahmad I, Borst I, Summebrbell RC (2000) Detection of xanthomegnin in epidermal materials infected with *Trichophyton rubrum*. *J Invest Dermatol* 115:901–905
23. Gupta AK, De Doncker P, Scher RK, Haneke E, Daniel CR 3d, Andre J, et al (1998) Itraconazole for the treatment of onychomycosis. *Int J Dermatol* 37:303-8.
24. Havu V, Brandt D, Heikkila H, Hollmen A, Oksman R, Rantanen T, et al. (1997) A double-blind, randomised study comparing itraconazole pulse therapy with continuous dosing for the treatment of toe-nail onychomycosis. *Br J Dermatol* 136:230-4.
25. De Doncker P, Decroix J, Pierard GE, Roelant D, Woestenborghs R, Jacqmin P, et al. (1996) Antifungal pulse therapy for onychomycosis. A pharmacokinetic and pharmacodynamic investigation of monthly cycles of 1-week pulse therapy with itraconazole. *Arch Dermatol* 132:34-41.
26. Scher RK (1999) Onychomycosis: therapeutic update. *J Am Acad Dermatol* 40(6 pt 2):S21-6.
27. Ciclopirox (Penlac) nail lacquer for onychomycosis (2000) *Med Lett Drugs Ther* 42(1080):51-2.
28. Dayan S, Damrose JF, Bhattacharyya TK, et al. (2003) Histological evaluations following 1,064-nm Nd:YAG laser resurfacing. *Lasers Surg Med* 33: 126-31.
29. Vural E, Winfield HL, Shingleton AW, Horn TD, Shafirstein G (2008) The effects of laser irradiation on *Trichophyton rubrum* growth, *Lasers Med Sci* 23: 349-353
30. Meral G, Tasar F, Kocagoz S et. al. (2003) Factors affecting the antibacterial effects of NdYAG laser in vivo. *Lasers in Surg Med.* 32(3):197-202.
31. Smijs TG, Schuitmaker HJ (2003) Photodynamic inactivation of the dermatophyte *Trichophyton rubrum*. *Photochem Photobiol* 77:556–560